

# Successful salvage for the intractable massive chylous leakage in a cirrhotic patient

## A case report and literature review

Chun-Lin Su, MD<sup>a</sup>, Geng-He Chang, MD<sup>b,c</sup>, Ku-Hao Fang, MD<sup>d</sup>, Chang-Cheng Chang, MD<sup>e,f,g,\*</sup>

### Abstract

**Rationale:** Iatrogenic chylous leakage (CL) is a rare but potentially life-threatening complication after neck surgery. In cirrhotic patient, the massive CL is even more intractable and extremely dangerous due to portal hypertension.

**Patients concerns:** A 54-year-old liver cirrhotic patient had milky fluid leakage from left neck drainage tube after neck dissection surgery and hypopharyngeal cancer ablation. Electrolyte imbalance and shock status were reported when conservative managements and exploratory surgical repair failed to terminate the leakage.

**Diagnosis:** Massive CL up to >5L/day was recorded on the post-operative day (POD) 9.

**Interventions:** A triangular-shaped pectoralis major (PM) muscle was designed to repair the lymph nodes dissected defect over left neck.

**Outcomes:** After surgery, CL dramatically reduced to less than 300mL/day in the coming day without relapses and terminated on the 8th days. After 3 months, the wound completely healed and the food conduit passage was patent without fistula.

**Lessons:** This report demonstrated the superiority of pectoralis major myocutaneous flap (PMMF) than the conservative treatment, local muscle flap, and radiologic or thoracoscopic duct ligation in cirrhotic patient with massive CL.

**Abbreviations:** ASM = anterior scalene muscle, CL = chylous leakage, PM = pectoralis major, PMMF = pectoralis major myocutaneous flap, POD = post-operative day, SCM = sternocleidomastoid muscle.

**Keywords:** chyle leak, chylous leakage, liver cirrhosis, neck dissection, pectoralis major flap

Editor: N/A.

*Ethics Approval:* All procedures performed were in accordance with the ethical standards of the institutional and/or national research committee and with the 1964 Helsinki Declaration. The study design was reviewed and approved by Chang Gung Medical Foundation Institutional Review Board (IRB number 102-0943B)

*Patient consent:* Informed consent was obtained from the participants prior to the study.

The authors have no funding and conflicts of interest to disclose.

<sup>a</sup> Department of Surgery, Chang Gung Memorial Hospital, Linkou, Taoyuan,

<sup>b</sup> Department of Otolaryngology-Head and Neck Surgery, <sup>c</sup> Center of Excellence for Chang Gung Research Datalink, Chang Gung Memorial Hospital, Chiayi,

<sup>d</sup> Department of Otolaryngology-Head and Neck Surgery, Chang Gung Memorial Hospital, Linkou, Taoyuan, <sup>e</sup> Division of Plastic and Reconstructive Surgery, Department of Surgery, China Medical University Hospital, <sup>f</sup> School of medicine, College of Medicine, China Medical University, Taichung, <sup>g</sup> Institute of Imaging and Biomedical Photonics, National Chiao Tung University, Tainan, Taiwan.

\* Correspondence: Chang-Cheng Chang, Division of Plastic and Reconstructive Surgery, Department of Surgery, China Medical University Hospital, Taichung, Taiwan School of medicine, College of Medicine, China Medical University, Taichung, Taiwan Institute of Imaging and Biomedical Photonics, National Chiao Tung University, Tainan, Taiwan No. 2, Yude Road, North District, Taichung City 404, Taiwan (ROC) (e-mail: changcc1975@gmail.com).

Copyright © 2017 the Author(s). Published by Wolters Kluwer Health, Inc. This is an open access article distributed under the terms of the Creative Commons Attribution-Non Commercial-No Derivatives License 4.0 (CCBY-NC-ND), where it is permissible to download and share the work provided it is properly cited. The work cannot be changed in any way or used commercially without permission from the journal.

Medicine (2017) 96:49(e9103)

Received: 25 August 2017 / Received in final form: 13 November 2017 /

Accepted: 14 November 2017

<http://dx.doi.org/10.1097/MD.00000000000009103>

## 1. Introduction

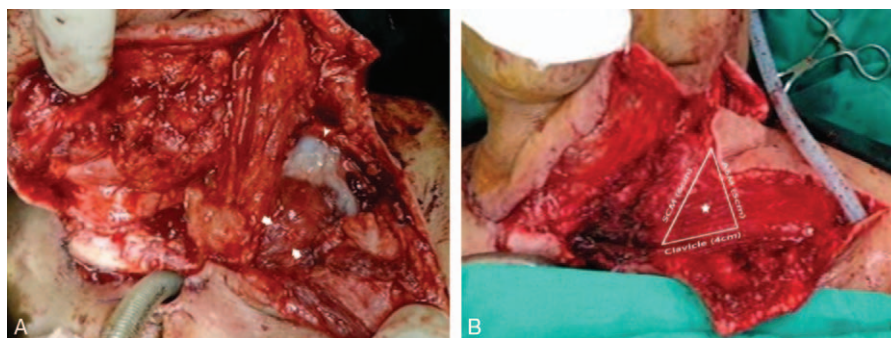
Iatrogenic chylous leakage (CL) is a rare but potentially life-threatening complication occurring in 1 to 2.5% of neck dissection surgery, and up to 75% of cases happens on the left side due to the usual course of thoracic duct.<sup>[1]</sup> Chylous extravasation may cause delayed wound healing, volume depletion, electrolyte imbalance, malnutrition, immunosuppression, and even severe sepsis and mortality.<sup>[2]</sup>

Liver cirrhosis is a major predisposing factor for massive CL because portal hypertension contributes to high thoracic ductal flow.<sup>[3]</sup> Thereby, massive CL with underlying liver cirrhosis is even more intractable and extremely dangerous. We present a successful salvaged case using pectoralis major myocutaneous flap (PMMF) to seal off massive CL in a cirrhotic patient.

## 2. Case report

A 54-year-old male with hypopharyngeal cancer (cT4aN2cM0) had underlying decompensated Child–Pugh score B liver cirrhosis with total bilirubin: 1.6 mg/dL, serum albumin: 3.2 g/dL, and prolonged prothrombin time (international normalized ratio: 1.6). He underwent total laryngopharyngectomy, bilateral modified radical neck dissection, and tubed anterolateral thigh free flap to reconduit the food pathway.

Milky fluid from left neck drainage tube was first observed on the post-operative day (POD) 3, and conservative managements failed to improve the condition. The massive CL up to >5L/day was recorded on the POD 9. The albumin level also plunged to 1.6 g/dL, accompanying with electrolyte imbalance (sodium: 118 mEq/L). We arranged a surgical exploration, where part of sternocleidomastoid (SCM) muscle was rotated to cover the



**Figure 1.** (A) In the exploratory surgical repair, a piece of the SCM was split and rotated to cover the region (white arrow) and fibrin glue was used to seal off the flap (white arrowhead). (B) In the salvaged 2nd operation, a triangular PMMF (white star) in size of 6 cm (SCM lateral border)  $\times$  5 cm (ASM medial border)  $\times$  4 cm (clavicle upper border) with a 6  $\times$  4 cm skin paddle was designed to obliterate the lower neck firmly. ASM=anterior scalene muscle, PMMF=pectoralis major myocutaneous flap, SCM=sternocleidomastoid muscle.

leaking sites (Fig. 1A). Nevertheless, massive CL  $>5$  L/day remained. A 5  $\times$  3 cm skin necrosis with purulent discharge from the lower neck wound was also observed. The hypovolemic shock status was encountered on the POD 21. A triangular-shaped PM muscle was designed on the POD 22 by measuring the distance between sternocleidomastoid muscle (SCM) and anterior scalene muscle (ASM) insertions on the clavicle as the base (4 cm), and the length of SCM lateral border (6 cm), and the ASM medial border (5 cm) as two limbs to fit the lymph nodes dissected defect over left neck zone V. We used 3-0 absorbable suture to reinforce the contact of PMMF to SCM and ASM (Fig. 1B). A

skin paddle (6  $\times$  4 cm) was also connected to resurface the skin defect. Dramatically, CL reduced to less than 300 mL/day in the coming day without relapses and terminated on the 8th days after salvaged surgery with PMMF. The wound healed well eventually without fistula formation or other significant comorbidity (Fig. 2). After 3 months, the wound completely healed and the food conduit passage was patent without fistula on esophagography.

### 3. Discussion

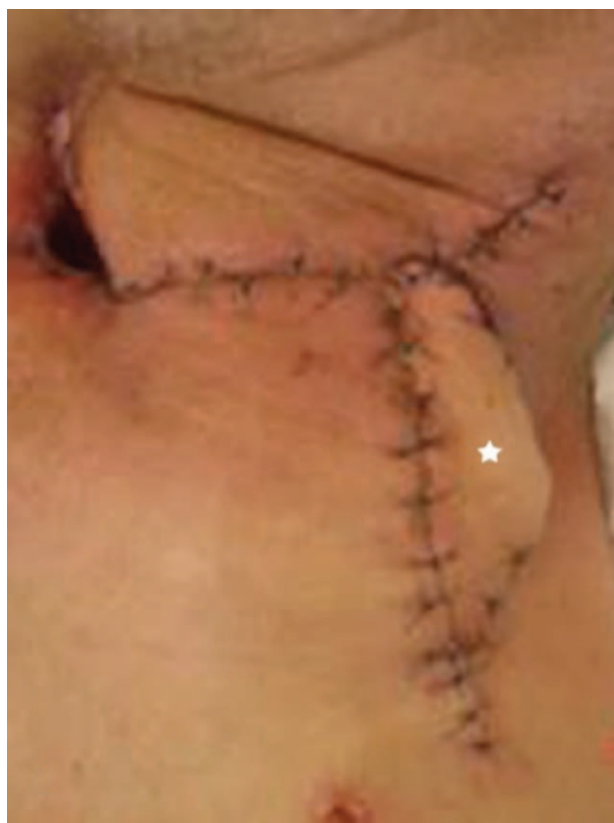The current management of CL includes conservative therapy, interventional radiology, thoracoscopic ligation, and surgical repair. Conservative therapy contains local pressure dressing, dietary modification with median chain triglyceride or fat-free diet,<sup>[4]</sup> total parental nutrition,<sup>[5]</sup> and pharmacotherapy with somatostatin analog, such as octreotide.<sup>[6]</sup> Duct embolization with lymphangiography, thoracoscopic duct ligation or local muscle flaps repair is usually required when the conservative therapy fails.<sup>[2]</sup>

These managements were reported efficient usually in less volume CL in the previous literatures. In de Gier et al's<sup>[1]</sup> paper, conservative treatment failed to terminate the CL  $>2.5$  L/day, which was finally closed by PMMF. Alejandro-Lafont et al<sup>[7]</sup> revealed that therapeutic lymphography succeeded in only 35% of the CL  $>500$  mL/day. Gunnlaugsson et al<sup>[8]</sup> demonstrated the effectiveness of thoracoscopic duct ligation in 3–4 L/day CL after conservative treatment failed.

Cirrhotic patients were reported to have 2 to 4 times greater diameter of thoracic duct and 3 to 6-folds increasing ductal flow rate,<sup>[3]</sup> which deteriorates the massive CL. In this case with massive CL and liver cirrhosis, PMMF, as a lifeboat, is feasibly accessed to cover the neck deep space for its bulkiness. Also it offers a sufficient skin paddle with adjacent proximity to resurface the cutaneous neck defect. After the literature review, once massive CL was concomitant with liver cirrhosis, the treatment strategy was suggested to be PMMF rather than trying conservative therapy, local flap repair or distal duct ligation.

### Reference

- [1] de Gier HH, Balm AJ, Bruning PF, et al. Systematic approach to the treatment of chylous leakage after neck dissection. *Head Neck* 1996;18:347–51.
- [2] Delaney SW, Shi H, Shokrani A, et al. Management of chyle leak after head and neck surgery: review of current treatment strategies. *Int J Otolaryngol* 2017;2017:8362874.



**Figure 2.** After salvaged surgery, the PMMF successfully terminated the intractable CL and the flap healed well without identified fistula. CL=chylous leakage, PMMF=pectoralis major myocutaneous flap.

- [3] Dumont AE, Mulholland JH. Flow rate and composition of thoracic-duct lymph in patients with cirrhosis. *N Engl J Med* 1960;263:471–4.
- [4] Martin I, Marinho L, Brown A, et al. Medium chain triglycerides in the management of chylous fistulae following neck dissection. *Brit J Oral Maxillofac Surg* 1993;31:236–8.
- [5] Bozzetti F, Arullani A, Batucci F, et al. Management of lymphatic fistulas by total parenteral nutrition. *JPEN J Parenter Enteral Nutr* 1982;6: 526–7.
- [6] Valentine CN, Barresi R, Prinz RA. Somatostatin analog treatment of a cervical thoracic duct fistula. *Head Neck* 2002;24: 810–3.
- [7] Alejandro-Lafont E, Krompiec C, Rau WS, et al. Effectiveness of therapeutic lymphography on lymphatic leakage. *Acta Radiol* 2011; 52:305–11.
- [8] Gunnlaugsson CB, Iannettoni MD, Yu B, et al. Management of chyle fistula utilizing thoracoscopic ligation of the thoracic duct. *ORL J Otorhinolaryngol Relat Spec* 2004;66:148–54.