

# Is carotid sonography a useful tool for predicting functional capabilities in ischemic stroke patients following carotid artery stenting?

Chih-Ming Lin, MD MPH<sup>a,b</sup>, Jian-Chi Su, MS<sup>c</sup>, Yu-Jun Chang, PhD<sup>d</sup>, Chi-Kuang Liu, MD<sup>e</sup>, Henry Horng-Shing Lu, PhD<sup>c,f,\*</sup>, Yuh-Jyh Jong, MD DMSci<sup>b,g,h,i,\*</sup>

## Abstract

Carotid stenosis is a major cause of stroke and timely intervention with stenting manipulation can significantly reduce the risk of secondary stroke. The impact of stenting procedures on patient functional capabilities has not yet been explored. The primary aim of this study was to examine associations between periprocedural carotid sonography parameters and post-treatment functional capabilities in stroke patients.

Sixty-seven patients who received carotid stenting at 1 angiography laboratory were included. Pre-stenting and post-stenting carotid duplex data were recorded and resistance index (RI) differences at various carotid system locations were compared. The modified Rankin Scale (mRS) was used to assess functional capability. All of the studied parameters were analyzed by SPSS (version 16.0, SPSS Inc, Chicago, IL).

Following stenting, mRS scores improved ( $n=44$ ) or remained stationary ( $n=23$ ). Net contralateral internal carotid artery (ICA) RI for patients with improved mRS was lower compared to that for patients with stationary mRS (median = 0.040 vs 0.11;  $P=0.003$ ). The contralateral common carotid artery RI before and after stenting differed significantly ( $P < 0.050$ ) in both. The ipsilateral ICA RI differed ( $P < 0.050$ ) only in patients with improved mRS. The difference in mean transit time, Barthel index, net ipsilateral ICA RI, net contralateral external carotid artery RI, postipsilateral common carotid artery RI, and postipsilateral ICA RI differed significantly between different baseline stroke severity groups ( $P < 0.050$ ).

Carotid artery stenting improved physical function in a proportion of ischemic stroke patients with carotid stenosis. Carotid ultrasound is a useful assessment tool to predict likely functional outcomes following carotid artery stenting.

**Abbreviations:** CBF = cerebral blood flow, CBV = cerebral blood volume, CCA = common carotid artery, CTA/P = computed tomography angiography and perfusion, DSA = digital subtraction angiography, ECA = external carotid artery, ICA = internal carotid artery, MRI/A = magnetic resonance imaging and angiography, mRS = modified Rankin Scale, MTT = mean transit time, OA = ophthalmic artery, RI = resistance index, TTP = time to peak.

**Keywords:** carotid artery stenting, carotid stenosis, ischemic stroke, modified Rankin Scale, resistance index

## 1. Introduction

Stroke is one of the leading causes of death worldwide. Carotid stenosis is the most well-known risk factor for stroke,<sup>[1]</sup> in part due to its association with recurrent stroke and lumen reduction

of >50% increases the risk of stroke or recurrent stroke by 2- to 3-fold.<sup>[2]</sup> It is well recognized that prompt management of carotid artery stenosis with stenting can prevent stroke or recurrent stroke.<sup>[3,4]</sup> However, associations between periprocedural carotid ultrasound parameters, baseline characteristics, and post-

Editor: Elena Cecilia Rosca.

Authorship: C-ML and Y-JJ performed study design and manuscript writing; J-CS performed data analysis and manuscript writing; Y-JC performed data analysis; C-KL collected data; HH-SL analyzed data and was instructor of study design.

Funding: This project is partially supported by Ministry of Science and Technology and Big Data Research Center of National Chiao Tung University, Taiwan.

The authors have no conflicts of interest to disclose.

Supplemental Digital Content is available for this article.

<sup>a</sup> Department of Neurology, Changhua Christian Hospital, Changhua, <sup>b</sup> Department and Institute of Biological Science and Technology, College of Biological Science and Technology, <sup>c</sup> Institute of Statistics, College of Science, National Chiao Tung University, Hsinchu, <sup>d</sup> Epidemiology and Biostatistics Center, <sup>e</sup> Department of Medical Imaging, Changhua Christian Hospital, Changhua, <sup>f</sup> Big Data Research Center, <sup>g</sup> Institute of Molecular Medicine and Bioengineering, College of Biological Science and Technology, National Chiao Tung University, Hsinchu, <sup>h</sup> Graduate Institute of Clinical Medicine, College of Medicine, <sup>i</sup> Departments of Pediatrics and Laboratory Medicine, Kaohsiung Medical University Hospital, Kaohsiung Medical University, Kaohsiung, Taiwan.

\* Correspondence: Henry Horng-Shing Lu, Institute of Statistics and Big Data Research Center, National Chiao Tung University, 1001 Ta Hsueh Road, Hsinchu 30010, Taiwan (e-mail: hslu@stat.nctu.edu.tw); Yuh-Jyh Jong, Department and Institute of Biological Science and Technology, College of Biological Science and Technology, National Chiao Tung University, 1001 Ta Hsueh Road, Hsinchu 30010, Taiwan (e-mails: yjjongnctu@gmail, yjjong@gap.kmu.edu.tw).

Copyright © 2017 the Author(s). Published by Wolters Kluwer Health, Inc.

This is an open access article distributed under the terms of the Creative Commons Attribution-Non Commercial License 4.0 (CCBY-NC), where it is permissible to download, share, remix, transform, and build upon the work provided it is properly cited. The work cannot be used commercially without permission from the journal.

Medicine (2017) 96:12(e6363)

Received: 24 February 2016 / Received in final form: 12 February 2017 / Accepted: 16 February 2017

<http://dx.doi.org/10.1097/MD.0000000000006363>

**Table 1****Baseline patient clinical characteristics.**

<b>N = 67</b>	<b>No., %, or median (range)</b>
Age, y	71 (47–86)
Gender (male)	56 (83.6%)
Body mass index, kg/m <sup>2</sup>	23.51 (14.8–36.3)
Weight, kg	60 (39–90)
Height, cm	160 (143–175)
Systolic blood pressure, mm Hg	139 (101–280)
Diastolic blood pressure, mm Hg	76 (52–112)
Admission Barthel index	90 (0–100)
Admission NIHSS score	3 (0–28)
Degree of stenosis in symptomatic side of carotid artery, %	76.4 (52.6–95)
Creatinine, mg/dL	1.08 (0.7–3.7)
Uric acid, mg/dL	6.60 (4.1–10.7)
Glycated hemoglobin, %	6.4 (5.1–12.6)
Fasting blood sugar, g/dL	109.5 (80–227)
Admission low-density lipoprotein, mg/dL	99 (47–175)
<b>Risk factor survey</b>	
	<b>No. (%)</b>
Chronic kidney disease	12 (17.9)
Gouty arthritis	10 (14.9)
Chronic heart failure	1 (1.5)
Atrial fibrillation	1 (1.5)
Hypertension	55 (82.1)
Diabetes mellitus	26 (38.8)
Dyslipidemia	50 (74.6)

NIHSS = National Institute of Health Stroke Scale.

treatment functional capabilities in first-time stroke patients have not been investigated.

Extracranial carotid ultrasound<sup>[5]</sup> is noninvasive and mobile, and requires no contrast medium, making it a useful assessment tool in carotid stenosis stroke patients.<sup>[6]</sup> However, the role of carotid ultrasound in evaluating the blood flow between the prestenting and poststenting phases has, to the best of our knowledge, not been reported or validated in stroke patients with carotid stenosis.

According to TOAST criteria<sup>[7–9]</sup> 30% to 35% of all acute ischemic stroke cases can be attributed to vascular atherosclerotic changes. There is an increased risk of recurrent stroke in this group of patients due to the high prevalence of moderate to severe stenosis with >50% lumen reduction. Carotid artery stenting can effectively prevent secondary stroke in addition to securing the main blood supply to the brain parenchyma<sup>[10–12]</sup> and the current guidelines<sup>[13–15]</sup> recommend carotid artery stenting when the diameter of the lumen is reduced by >70%, if assessed by noninvasive imaging, or >50%, if assessed by catheter-based imaging. Despite the efficacy of carotid artery stenting being well established in ischemic stroke patients with stenosis, the documented outcomes for these patients are heterogeneous, and the procedure may be associated with significant morbidity.<sup>[16,17]</sup>

The primary aim of this study was therefore to investigate whether the functional outcomes following carotid artery stenting in first-time stroke patients with carotid stenosis were associated with baseline characteristics and/or parameters measured by ultrasound. Changes in the resistance index (RI) values at various locations on the ipsilateral and contralateral carotid systems were investigated to determine whether the RI plays a role in the early prediction of outcomes.

## 2. Materials and methods

A total of 67 ischemic stroke patients, experiencing their first stroke, who had received carotid artery stenting at the angiography laboratory of the Department of Medical Imaging of Changhua Christian Hospital, Changhua, Taiwan, were enrolled in this study. Patients were transferred from an outpatient clinic, an emergency department, or a branch hospital and were subsequently admitted to Changhua Christian hospital for examination and treatment. Inclusion criteria were the following: a history of an initial, first-time, ischemic stroke, with the cause of stroke confirmed as due to carotid stenosis, age >20 years, carotid stenosis >50% lumen reduction by angiography, no documentation of recurrent stroke during the study period, and follow-up available for at least 12 months following the stenting procedure. All patients had ischemic infarctions in the middle cerebral artery (MCA) territory verified by imaging. Patients were excluded if they had cerebral hemorrhage, cerebral arteriovenous malformations and aneurysms, or bilateral moderate to severe carotid stenosis. Patients who were lost to follow-up and those who were followed up for <12 months after stenting were also excluded.

All included patients were stented 1 month after the index stroke event by the same neuroradiologist (Dr Chi-Kuang Liu). Carotid ultrasound was conducted before stenting and 4 weeks after the procedure. Follow-up was for an average of 1 year allowing for assessment of midterm functional outcomes. All patients had a detailed history of baseline (Table 1) and biochemical characteristics and had undergone neuroimaging examinations (digital subtraction angiography [DSA], computed tomography angiography and perfusion [CTA/P], and magnetic resonance imaging and angiography [MRI/A]) before stenting. The study was approved by the Institutional Review Board of Changhua Christian Hospital. The study was retrospective and the informed consent was not required by the Institutional Review Board of Changhua Christian Hospital (see appendix IRB approval, <http://links.lww.com/MD/B607>).

### 2.1. Baseline patient clinical characteristics

Patient demographics and pertinent risk factors (gender, age, diabetes mellitus, hypertension, dyslipidemia, Barthel index, atrial fibrillation, chronic heart failure, gouty arthritis, chronic kidney disease, body mass index, weight, height, systolic blood pressure, diastolic blood pressure, and admission score of National Institute of Health Stroke Scale) along with biochemical parameters (creatinine, low-density lipoprotein, uric acid, fasting blood sugar, and glycated hemoglobin levels) were abstracted from patient medical records to a standardized form. The modified Rankin Scale (mRS) was used to evaluate patient functional capacity. Each patient was evaluated at least twice using the mRS, before stenting and after the stenting procedure, in an outpatients' clinic, with a minimum of 12 months between the 2 assessments. An mRS score of 0 to 1 generally indicates neurological stability, although mild neurological symptoms may be noticed; a score of 2 to 3 denotes moderately affected daily life activity; and a score of ≥4 indicates that intensive care is required and there is a high risk of death. The Barthel index was recorded before stenting and patients were classified into 2 comparison groups (Barthel index 0–60 vs 61–100).<sup>[18,19]</sup>

### 2.2. Cervical carotid ultrasound examination

Cervical carotid artery ultrasound examination was performed at our ultrasonography laboratory (Philips iE33 7-MHz linear

transducer). Cross-sectional B-mode scanning was performed to check for intraluminal plaque and the longitudinal screening method was adopted to confirm the presence of plaque. The classification of plaques into subtypes 1, 2, 3, or 4 according to the International Classification System<sup>[20]</sup> was assessed by consensus of 2 physicians. In case of a disagreement between the physicians, a third physician assessed the classification. The intima-media thickness of the midportion of the common carotid artery (CCA) was measured on the ipsilateral side of the index stroke event. Peak systolic velocity, end-diastolic velocity, and the RI of the CCA, internal carotid artery (ICA), external carotid artery (ECA), and ophthalmic artery (OA) were measured bilaterally; reversal of blood flow in the OA was also measured. Forward flow was defined as blood flow detected away from the stenotic ipsilateral carotid artery, whereas reverse flow was defined as blood flow into the carotid artery. The degree of carotid stenosis and parameter classification was calculated according to the European Carotid Surgery Trial method.<sup>[21]</sup> The calculated ICA/CCA ratio<sup>[22,23]</sup> was defined as the ratio of the peak systolic velocity of the ICA to that of the CCA for each patient.

The RI data from pre-stenting and post-stenting phases were integrated. RI parameters regarding the bilateral carotid systems of the patients are defined as follows, and each set of RI parameters was tested to determine the statistical significance:

1. Net RI: The absolute pre-stenting and post-stenting RI values of each location in the carotid examination
2. Ratio RI: The pre-stenting and post-stenting RI values of each location in the carotid examination

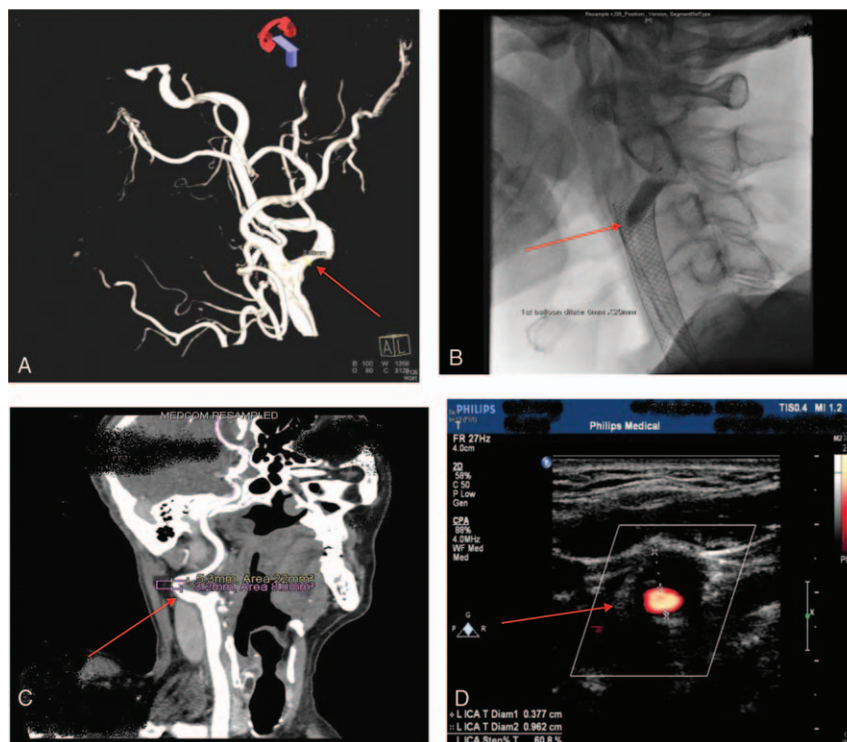
3. Pre-RI: The RI value of each location before stenting in the carotid examination
4. Post-RI: The RI value of each location after stenting in the carotid examination

**2.3. Neuroradiological examinations**

**2.3.1. Magnetic resonance imaging and angiography.** Structural and functional magnetic resonance imaging (MRI) and angiographic examinations were performed using a standard stroke evaluation protocol using a 3-T MRI scanner (MAGNETOM Verio, Siemens Healthcare, Malvern, PA) or 1.5-T MRI scanner (MAGNETOM Aera, Siemens Healthcare) with a cervical coil. The entire imaging time was approximately 7 minutes. The following 3 parameters were derived from MRI/A:

1. Ipsilateral MCA stenosis or occlusion represented whether the patients had concomitant MCA focal stenosis or occlusion on magnetic resonance angiography (MRA), which was confirmed through DSA.
2. Intracranial posterior circulation stenosis or occlusion represented whether the patients had incidental (either intracranial vertebral or basilar artery) focal stenosis or occlusion on MRA, which was confirmed through DSA.
3. Stroke location was categorized into cortical, subcortical, and cortical and subcortical regions.

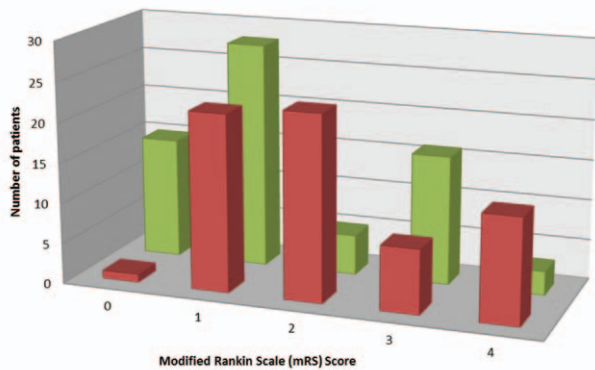
**2.3.2. DSA and stenting.** The stenting procedure is illustrated in Fig. 1. Biplanar intra-arterial DSA was performed using a



**Figure 1.** An example of left-sided severe internal carotid artery stenosis undergoing carotid stenting treatment. A 67-year-old male patient manifested with right-sided hemiparesis and dysarthria, 24 hours before admission to our neurology ward. (A) Reconstruction imaging of digital subtraction angiography showed a short segmental high-grade stenosis (>70%) involving the proximal part of left internal carotid artery. (B) The insertion of E-Z wire to prevent distal emboli migration. After the stent was placed, a 6 × 20 mm balloon catheter was used for postdilatation purpose. (C) The computed tomographic angiography (CTA) showed evidence of segmental stenosis at left cervical internal carotid artery, severe degree (64% based on area measurement). (D) B-mode imaging of cervical color-coded carotid duplex showed 60.8% stenosis detected by the cross-sectional maneuver.



**mRS score in ischemic stroke patients before and after carotid artery stenting**



	0	1	2	3	4
Before stenting procedure	1	22	23	8	13
After stenting procedure	15	28	5	16	3

**Figure 2.** mRS score in ischemic stroke patients before and after carotid artery stenting. mRS=modified Rankin Scale.

biplanar flap panel rotational angiography unit (Axiom Artis Zee, Siemens Healthcare). A self-expanding Carotid Wallstent (7 × 30 mm) was used. The stent was delivered coaxially through the guiding catheter into the stenotic area.

**2.3.3. CTA/PA imaging.** Computed tomography angiography examinations were performed using a second-generation dual-source computed tomography scanner (SOMATOM Definition Flash, Siemens Healthcare, Forchheim, Germany). Perfusion data sets were postprocessed on a Siemens Multimodality Workplace Workstation (Siemens Medical, Erlangen, Germany), yielding mean transit time (MTT), cerebral blood volume (CBV), cerebral blood flow (CBF), and time to peak (TTP) maps. Other CTP parameters<sup>[24–27]</sup> were evaluated and defined as follows to test for association with the mRS score:

1. Difference of mean transit time (dMTT): (Absolute value of the ipsilateral MTT) – (contralateral MTT of each patient)
2. rCBV: CBV ratio ([ipsilateral CBV]/[contralateral CBV])
3. CBV index: (([ipsilateral CBV] – [contralateral CBV]) / (contralateral CBV))
4. rCBF: CBF ratio ([ipsilateral CBF]/[contralateral CBF])
5. CBF index: (([ipsilateral CBF] – [contralateral CBF]) / (contralateral CBF))
6. TTP index: (([ipsilateral TTP] – [contralateral TTP]) / (contralateral TTP))
7. rMTT: MTT ratio ([ipsilateral MTT]/[contralateral MTT])

**2.4. Statistical analyses**

All statistical analyses were performed using the statistical package SPSS for Windows (version 16.0, SPSS Inc, Chicago, IL).

Prestenting and poststenting mRS scores were compared to determine patient outcomes and classified as improved, stationary, or deteriorated. Statistical comparisons were conducted using Pearson  $\chi^2$  test.

Following classification, comparison of groups according to poststenting mRS score was conducted using all available recorded variables. The Mann–Whitney *U* test was used to determine

differences in the means of continuous variables between the 2 groups. Categorical variables were compared using the  $\chi^2$  test, or Fisher exact test, where appropriate. Univariate or multivariate logistic regression was employed to assess the significance of risk factors and to obtain odds ratios. A *P* value <0.050 was considered statistically significant. To further differentiate the 2 groups, the Wilcoxon signed-rank test was used to evaluate differences between the prestenting and poststenting RI values at each location in the bilateral carotid systems (CCA, ICA, ECA, and OA).

Further subgroup analysis was conducted in those patients showing improvement following stenting. Groups were differentiated on the basis of stroke severity as determined by mRS score; patients were categorized into 3 groups as follows: mild (mRS score improvement from 1 to 0 following stenting; n=13), moderate (mRS score change from 2 to 1; n=18), and severe (mRS score change from 4 to 3; n=10). The Kruskal–Wallis test was used to determine whether any variable exhibited a significant difference among the 3 groups and the Jonckheere–Terpstra test was utilized to test for significance of trends.<sup>[28,29]</sup>

**3. Results**

Baseline characteristics are given in Table 1. Improved mRS score following stenting was observed in 44/67 (65.7%) ischemic stroke patients. In total, 42 patients improved by 1 point on the mRS scale and 2 patients improved by 2 points. The condition remained unchanged (stationary) in the remaining 23/67 (34.3%) patients after stenting (see Fig. 2; appendix supplementary table, <http://links.lww.com/MD/B607>).

When patients with an improved mRS score were compared to those with a stationary mRS score, no statistically significant differences were observed for any of the clinical parameters investigated, apart from net contralateral ICA RI. Net contralateral ICA RI was significantly lower following stenting in those patients exhibiting improved functioning, with a median ICA RI of 0.04 for patients with improved mRS compared to 0.11 for those with stationary mRS (*P*=0.003; univariate analysis: odds ratio 5.279; 95% confidence interval 2.123, 12.342; *P*=0.005).

In further analysis of the 2 groups, each RI location was compared for the prestenting and poststenting phases at various sites of the carotid systems (Table 2). The contralateral CCA RI for the stationary and improvement mRS groups differed significantly (0.76 vs 0.80; Wilcoxon signed-rank test, *P*=0.008 and 0.009, respectively), whereas for the improved mRS group the ipsilateral ICA RI differed significantly following stenting (0.62 vs 0.71, respectively; *P*=0.002).

In a subgroup analysis, patients showing improved mRS after stenting were divided into 3 groups (mild, moderate, and severe) based on their mRS score. There were no statistically significant differences between the 3 groups with respect to clinical parameters, apart from the Barthel index at admission (Barthel index 0–60 vs 61–100; *P*<0.050) (Table 3), dMTT, net ipsilateral ICA RI, net contralateral ECA RI, postipsilateral CCA RI, and postipsilateral ICA RI (*P*=0.019, 0.045, 0.020, 0.025, and 0.032, respectively) (Table 4).

In addition, as baseline mRS scores increased from mild to severe, the median values of the dMTT, postipsilateral CCA RI, and postipsilateral ICA RI also had a tendency to increase (Jonckheere–Terpstra test; *P*<0.050).

**4. Discussion**

In the present study, no patients exhibited deterioration in mRS score following stenting and over half of the patients (65.7%) had

**Table 2**  
Periprocedural changes of the RI in the ipsilateral and contralateral carotid systems.

RI	Function stationary after treatment (N=23)			Function improved after treatment (N=44)		
	Prestenting median (range)	Poststenting median (range)	P value	Prestenting median (range)	Poststenting median (range)	P value*
Ipsilateral CCA	0.79 (0.66–0.92)	0.77 (0.63–1.00)	NS	0.78 (0.60–0.90)	0.78 (0.61–1.00)	NS
Ipsilateral ICA	0.61 (0.20–1.00)	0.71 (0.50–0.89)	NS	0.62 (0.36–0.92)	0.71 (0.50–0.89)	0.002
Ipsilateral ECA	0.89 (0.72–1.00)	0.88 (0.80–1.00)	NS	0.88 (0.76–1.00)	0.90 (0.58–1.00)	NS
Ipsilateral OA	0.81 (0.42–1.00)	0.83 (0.68–1.00)	NS	0.74 (0.49–1.00)	0.83 (0.51–1.00)	NS
Contralateral CCA	0.76 (0.64–0.86)	0.80 (0.65–0.94)	0.008	0.76 (0.50–1.00)	0.80 (0.37–0.96)	0.009
Contralateral ICA	0.68 (0.38–1.00)	0.74 (0.58–0.87)	NS	0.68 (0.53–0.90)	0.70 (0.40–1.00)	NS
Contralateral ECA	0.91 (0.75–1.00)	0.92 (0.78–1.00)	NS	0.87 (0.75–1.00)	0.89 (0.70–1.00)	NS
Contralateral OA	0.83 (0.61–1.00)	0.84 (0.60–1.00)	NS	0.80 (0.30–1.00)	0.84 (0.60–1.00)	NS

CCA=common carotid artery, ECA=external carotid artery, ICA=internal carotid artery, NS=not significant, OA=ophthalmic artery, RI=resistance index.  
\* P<0.05, statistically significant.

improved mRS score, with the remainder having stationary or stable scores. This provides an indication that, in this patient series, carotid artery stenting was associated with improved outcomes in a substantial proportion of patients.

Carotid endarterectomy is an effective prophylactic procedure against stroke for patients with carotid stenosis discovered as an incidental finding,<sup>[30–32]</sup> although carotid stenting is a less invasive treatment and has been shown to be as beneficial as endarterectomy in patients with angiographic evidence of >60% stenosis or ultrasonographic evidence of 70% stenosis in primary prevention.<sup>[33]</sup> Treatment of patients with ischemic stroke and concomitant carotid stenosis is more complex. In patients of advanced age, carotid endarterectomy is preferred over carotid stenting because it has been shown to be associated with better outcome. All of the patients in this study underwent carotid stenting, even though most were of advanced age (median age 71 years), as there was no facility for carotid endarterectomy services at the institute where the study was conducted.

Computed tomography perfusion scanning is the standard tool for assessing cerebral perfusion in patients who undergo stenting<sup>[34–36]</sup> but requires the use of contrast medium that can result in significant morbidity, particularly in patients with impaired renal function. Extracranial carotid ultrasound has several advantages as it is noninvasive, mobile, and inexpensive and requires no contrast medium. The use of carotid ultrasound for assessing patients in this study and measurement of carotid duplex data at follow-up 4 weeks after stenting allows relatively immediate assessment of the effect of stenting. Combining carotid duplex data, parameters measured using carotid ultrasound, and patient condition at baseline and 12 months after stenting allows for the examination of any association between these variables and outcomes. To date no studies have examined the role of carotid artery RI in evaluating cerebral perfusion status after carotid stenting in first-time ischemic stroke patients, although RI

has been widely used in nephrology.<sup>[37]</sup> Derchi et al measured RI in patients with renal dysfunction and reported that the risk of renal impairment increased 2-fold when renal RI was >0.63.<sup>[37]</sup> In addition, RI is effective in predicting kidney transplant outcomes.<sup>[37–42]</sup> The RI represents the general downstream blood vascular bed resistance level.<sup>[43]</sup> RI >0.75 denotes increased resistance of the downstream vascular bed, which can arise as a result of various factors including obstructions. Because CCA and ICA supply the majority of blood to the intracranial hemispheres, their RI values are lower than that of ECA under normal circumstances (CCA and ICA <0.75, ECA >0.75).

In the first-time ischemic stroke patients investigated in the present study net contralateral ICA RI was the most useful measurement for differentiating between patients whose mRS score remained stationary and those whose mRS score improved. The median net contralateral ICA RI value in the stationary group was >2-fold higher than that of the improved group (P=0.005). This indicates that lower net contralateral ICA values measured in the persisting period may be predictive of positive outcomes at 12-month follow-up, whereas higher values are less likely to be associated with improvement in mRS score at 12 months.

In the series of first-time ischemic stroke patients studied, following carotid artery stenting the ipsilateral CCA RI values tended to decrease, whereas those at other locations of the bilateral carotid systems mostly increased (Table 2). The CCA RI predicts the downstream vascular resistance bed, particularly in the ICA region. After stenting, the resistance is alleviated. The downstream vascular bed of the distal ICA, which can be revealed by the proximal ICA RI value, subsequently constricts the downstream vascular bed resulting in a relatively high resistance value; in other words, it may cancel out any increase in blood flow.<sup>[44,45]</sup>

**Table 3**  
Correlation between the Barthel index and 3 baseline mRS groups for patients with improved function after stenting.

	mRS			P value <0.050*
	Mild, n (%)	Moderate, n (%)	Severe, n (%)	
Barthel index	0–60	0 (0.0)	2 (11.1)	7 (70)
	61–100	13 (100)	16 (88.9)	3 (30)

mRS=modified Rankin Scale.  
\* P<0.05, statistically significant.

**Table 4**  
Critical clinical parameters in the 3 different baseline mRS groups.

Median	mRS			P value
	Mild	Moderate	Severe	
dMTT	0.58	0.84	1.70	0.019
Net ipsilateral ICA RI	0.09	0.06	0.16	0.045
Net contralateral ECA RI	0.02	0.06	0.03	0.020
Postipsilateral CCA RI	0.76	0.76	0.82	0.025
Postipsilateral ICA RI	0.70	0.67	0.75	0.032

CCA=common carotid artery, dMTT=difference of mean transit time, ECA=external carotid artery, ICA=internal carotid artery, mRS=modified Rankin Scale, RI=resistance index.

In a subgroup analysis, patients were divided into 3 different baseline severity groups and it was found that, regardless of baseline mRS score, the improvement was uniform across all groups with an average 1-point decrease in score for each group, regardless of baseline severity. This is consistent with existing studies that have classified patients according to mRS score.<sup>[46–48]</sup> Furthermore, it was identified that of the 6 significant parameters, 4 were related to the RI, highlighting the importance of carotid ultrasound as an assessment tool.

Reversal of ophthalmic artery flow (ROAF) may result from intracranial hemodynamic compromise. Patients with unilateral high-grade cervical carotid stenosis in combination with intracranial stenosis appear to be at significantly increased risk for poor functional outcome and increased incidence of both intracranial stenosis<sup>[49]</sup> and ROAF.<sup>[50]</sup> Intracranial stenosis is a major stroke risk indicator as well as a predictor for worse stroke outcomes, and ROAF may provide partial compensation for improving stroke outcomes.<sup>[49]</sup>

Strengths of this study include that there was sufficient difference in time, of at least 12 months, between administering the first mRS test and the follow-up mRS. Furthermore, follow-up mRS was performed at an outpatient clinic that facilitated reproducibility of results and enabled patients' neurological condition to stabilize following the stenting procedure.

Limitations of this study include that it was conducted at a single medical center with only 67 patients, and, hence, the sample size was small. The study results must be interpreted cautiously, and additional studies on larger samples sizes are required to confirm these findings. In addition, a control group for comparison with the experimental group was not included and all participants in this study were Asian and, therefore, the results may be relevant only to an Asian population. Poststenting neuroimaging such as brain MRI/A or CTA/P was not routinely arranged but would have added to this study. It is also possible that some subclinical stroke events following stenting may have been missed in this patient population, and this may have resulted in misinterpretation of the data. Finally, the patients were treated with dual antiplatelet therapy for at least 6 months after stenting. Stroke patients who had concomitant morbidities such as diabetes mellitus were also treated with appropriate drug therapy. The poststenting drug therapy might potentially confound the subsequent mRS value and therefore alter the functionality correlation.

Nevertheless, we have shown that carotid artery stenting has the capacity to improve mRS score in a proportion of ischemic stroke patients with carotid artery stenosis. Measurements of RI assessed by carotid ultrasound at 4 weeks poststenting correlate with midterm functional outcomes and may assist physicians in predicting the likely mRS score at 12 months following carotid artery stenting.

## Acknowledgments

With special thanks to Mu-Chien Sun, MD, MS of Stroke Center, Changhua Christian Hospital for his great support, and Ping-Yi Lin, PhD of Changhua Christian Hospital for her constructive comments.

## References

- Cremonesi A, Castriota F, Secco GG, et al. Carotid artery stenting: an update. *Eur Heart J* 2015;36:13–21.
- Morr S, Lin N, Siddiqui AH. Carotid artery stenting: current and emerging options. *Med devices (Auckl)* 2014;7:343–55.
- Papanagiotou P, Roth C, Walter S, et al. Carotid artery stenting in acute stroke. *J Am Coll Cardiol* 2011;58:2363–9.
- Xia ZY, Yang H, Xu JX, et al. Effect of stenting on patients with chronic internal carotid artery occlusion. *Int Angiol* 2012;31:356–60.
- Lee CJ, Park S. The role of carotid ultrasound for cardiovascular risk stratification beyond traditional risk factors. *Yonsei Med J* 2014;55:551–7.
- Lim S, Chang Y, Lin S. Extracranial carotid artery disease: risk factors and outcomes in patients with acute critical hemispheric ischemic stroke. *J Ultrasound Med* 2016;35:341–8.
- Adams HPJr, Bendixen BH, Kappelle LJ, et al. Classification of subtype of acute ischemic stroke. Definitions for use in a multicenter clinical trial. TOAST. Trial of Org 10172 in Acute Stroke Treatment. *Stroke*; 1993;24:35–41.
- Kolominisky-Rabas PL, Weber M, Gefeller O, et al. Epidemiology of ischemic stroke subtypes according to TOAST criteria: incidence, recurrence, and long-term survival in ischemic stroke subtypes: a population-based study. *Stroke* 2001;32:2735–40.
- Madden KP, Karanjia PN, Adams HPJr, et al. Accuracy of initial stroke subtype diagnosis in the TOAST study. Trial of ORG 10172 in Acute Stroke Treatment. *Neurology* 1995;45:1975–9.
- Chaturvedi S, Sacco RL. How recent data have impacted the treatment of internal carotid artery stenosis. *J Am Coll Cardiol* 2015;65:1134–43.
- Meyer SA, Gandhi CD, Johnson DM, et al. Outcomes of carotid artery stenting in high-risk patients with carotid artery stenosis: a single neurovascular center retrospective review of 101 consecutive patients. *Neurosurgery* 2010;66:448–53. [discussion 53–54].
- Spence JD. Management of asymptomatic carotid stenosis. *Neurol Clin* 2015;33:443–57.
- Kernan WN, Ovbiagele B, Kittner SJ. Response to letter regarding article, “Guidelines for the prevention of stroke in patients with stroke and transient ischemic attack: a guideline for healthcare professionals from the American Heart Association/American Stroke Association”. *Stroke* 2015;46:e87–9.
- Brott TG, Halperin JL, Abbara S, et al. 2011 ASA/ACCF/AHA/AANN/AANS/ACR/ASNR/CNS/SAIP/SCAI/SIR/SNIS/SVM/SVS guideline on the management of patients with extracranial carotid and vertebral artery disease: executive summary. *J Neurointerv Surg* 2011;3:100–30.
- Kernan WN, Ovbiagele B, Black HR, et al. Guidelines for the prevention of stroke in patients with stroke and transient ischemic attack: a guideline for healthcare professionals from the American Heart Association/American Stroke Association. *Stroke* 2014;45:2160–236.
- Vogel TR, Dombrowskiy VY, Haser PB, et al. Outcomes of carotid artery stenting and endarterectomy in the United States. *J Vasc Surg* 2009;49:325–30. [discussion 30].
- Zhang L, Zhao Z, Ouyang Y, et al. Systematic review and meta-analysis of carotid artery stenting versus endarterectomy for carotid stenosis: a chronological and worldwide study. *Medicine* 2015;94:e1060.
- Shah S, Vanclay F, Cooper B. Predicting discharge status at commencement of stroke rehabilitation. *Stroke* 1989;20:766–9.
- Shah S, Vanclay F, Cooper B. Improving the sensitivity of the Barthel index for stroke rehabilitation. *J Clin Epidemiol* 1989;42:703–9.
- Gray-Weale AC, Graham JC, Burnett JR, et al. Carotid artery atheroma: comparison of preoperative B-mode ultrasound appearance with carotid endarterectomy specimen pathology. *J Cardiovasc Surg* 1988;29:676–81.
- MRC European Carotid Surgery Trial: interim results for symptomatic patients with severe (70–99%) or with mild (0–29%) carotid stenosis. European Carotid Surgery Trialists' Collaborative Group. *Lancet* 1991;337:1235–43.
- Grant EG, Benson CB, Moneta GL, et al. Carotid artery stenosis: grayscale and Doppler ultrasound diagnosis—Society of Radiologists in Ultrasound consensus conference. *Ultrasound Q* 2003;19:190–8.
- Hunink MG, Polak JF, Barlan MM, et al. Detection and quantification of carotid artery stenosis: efficacy of various Doppler velocity parameters. *AJR Am J Roentgenol* 1993;160:619–25.
- Jongen LM, van der Worp HB, Waaijer A, et al. Interrelation between the degree of carotid stenosis, collateral circulation and cerebral perfusion. *Cerebrovasc Dis* 2010;30:277–84.
- Kluytmans M, van der Grond J, van Everdingen KJ, et al. Cerebral hemodynamics in relation to patterns of collateral flow. *Stroke* 1999;30:1432–9.
- Pinero P, Gonzalez A, Moniche F, et al. Progressive changes in cerebral perfusion after carotid stenting: a dynamic susceptibility contrast perfusion weighted imaging study. *J Neurointerv Surg* 2014;6:527–32.
- Trojanowska A, Drop A, Jargiello T, et al. Changes in cerebral hemodynamics after carotid stenting: evaluation with CT perfusion studies. *J Neuroradiol* 2006;33:169–74.

- [28] Jonckheere AR. A distribution-free k-sample test against ordered alternatives. *Biometrika* 1954;41:133–45.
- [29] Terpstra TJ. The asymptotic normality and consistency of Kendall's test against trend, when ties are present in one ranking. *Indagationes Mathematicae* 1952;14:327–33.
- [30] North American Carotid Endarterectomy Trial Collaborators. Beneficial effect of carotid endarterectomy in symptomatic patients with high-grade carotid stenosis. *N Engl J Med* 1991;325:445–53.
- [31] Barnett HJ, Taylor DW, Eliasziw M, et al. Benefit of carotid endarterectomy in patients with symptomatic moderate or severe stenosis. North American Symptomatic Carotid Endarterectomy Trial Collaborators. *N Engl J Med* 1998;339:1415–25.
- [32] Hugl B, Oldenburg WA, Neuhauser B, et al. Effect of age and gender on restenosis after carotid endarterectomy. *Ann Vasc Surg* 2006;20:602–8.
- [33] Meschia JF, Bushnell C, Boden-Albala B, et al. Guidelines for the primary prevention of stroke: a statement for healthcare professionals from the American Heart Association/American Stroke Association. *Stroke* 2014;45:3754–832.
- [34] Duan Y, Li G, Yang Y, et al. Changes in cerebral hemodynamics after carotid stenting of symptomatic carotid artery. *Eur J Radiol* 2012;81:744–8.
- [35] Szarmach A, Halena G, Buczny J, et al. Evaluation of changes in the parameters of brain tissue perfusion in multi-slice computed tomography in patients after carotid artery stenting. *Pol J Radiol* 2011;76:7–15.
- [36] Thierfelder KM, Sommer WH, Baumann AB, et al. Whole-brain CT perfusion: reliability and reproducibility of volumetric perfusion deficit assessment in patients with acute ischemic stroke. *Neuroradiology* 2013;55:827–35.
- [37] Derchi LE, Leoncini G, Parodi D, et al. Mild renal dysfunction and renal vascular resistance in primary hypertension. *Am J Hypertens* 2005;18:966–71.
- [38] Naesens M, Heylen L. Intrarenal resistive index after renal transplantation. *N Engl J Med* 2014;370:677–8.
- [39] Viazzi F, Leoncini G, Derchi LE, et al. Ultrasound Doppler renal resistive index: a useful tool for the management of the hypertensive patient. *J Hypertens* 2014;32:149–53.
- [40] Heine GH, Gerhart MK, Ulrich C, et al. Renal Doppler resistance indices are associated with systemic atherosclerosis in kidney transplant recipients. *Kidney Int* 2005;68:878–85.
- [41] Heine GH, Reichart B, Ulrich C, et al. Do ultrasound renal resistance indices reflect systemic rather than renal vascular damage in chronic kidney disease? *Nephrol Dial Transplant* 2007;22:163–70.
- [42] Kolonko A, Szotowska M, Kuczera P, et al. Extrarenal factors influencing resistance index in stable kidney transplant recipients. *Transplantation* 2013;96:406–12.
- [43] Pourcelot L. Applications cliniques de l'Examen Doppler Transcutane. Les Colloques de L'Institute National de la Sante et de la Recherche Medicale. INSERM 1974;34:213–40.
- [44] Roman MJ, Naqvi TZ, Gardin JM, et al. Clinical application of noninvasive vascular ultrasound in cardiovascular risk stratification: a report from the American Society of Echocardiography and the Society of Vascular Medicine and Biology. *J Am Soc Echocardiogr* 2006;19:943–54.
- [45] Stein JH, Korcarz CE, Hurst RT, et al. Use of carotid ultrasound to identify subclinical vascular disease and evaluate cardiovascular disease risk: a consensus statement from the American Society of Echocardiography Carotid Intima–Media Thickness Task Force. Endorsed by the Society for Vascular Medicine. *J Am Soc Echocardiogr* 2008;21:93–111. [quiz 89–90].
- [46] Burn JP. Reliability of the modified Rankin Scale. *Stroke* 1992;23:438.
- [47] Patel N, Rao VA, Heilman-Espinoza ER, et al. Simple and reliable determination of the modified Rankin Scale score in neurosurgical and neurological patients: the mRS-9Q. *Neurosurgery* 2012;71:971–5. [discussion 5].
- [48] Wilson JT, Hareendran A, Hendry A, et al. Reliability of the modified Rankin Scale across multiple raters: benefits of a structured interview. *Stroke* 2005;36:777–81.
- [49] Sung Y, Tsai C, Lee J, et al. Reversal of ophthalmic artery flow and stroke outcomes in Asian patients with acute ischemic stroke and unilateral severe cervical carotid stenosis. *PLoS One* 2013;8:e80675.
- [50] Tsai CL, Lee JT, Cheng CA, et al. Reversal of ophthalmic artery flow as a predictor of intracranial hemodynamic compromise: implication for prognosis of severe carotid stenosis. *Eur J Neurol* 2013;20:564–70.