

Case report

QJM

Benign reversible course in infants manifesting clinicopathological features of fatal mitochondrial myopathy due to m.14674 T>C mt-tRNA^{Glu} mutation

T.-H. CHEN^{1,2}, Y.-F. TU³, Y.-I. GOTO⁴ and Y.-J. JONG^{2,5,6}

From the ¹Division of Pediatric Emergency, Department of Emergency, ²Department of Pediatrics, Kaohsiung Medical University Hospital, Kaohsiung Medical University, Kaohsiung 80708, Taiwan, ³Department of Pediatrics, National Cheng Kung University Hospital, Tainan 704, Taiwan, ⁴Department of Mental Retardation and Birth Defect Research, National Institute of Neuroscience, National Center of Neurology and Psychiatry, Tokyo 187-8502, Japan, ⁵Graduate Institute of Medicine, College of Medicine, Kaohsiung Medical University, Kaohsiung 80708, and ⁶Department of Biological Science and Technology, National Chiao Tung University, Hsin-Chu 300, Taiwan

Address correspondence to Dr Yuh-Jyh Jong, Department of Pediatrics, Kaohsiung Medical University Hospital, No. 100, Tzyou 1st Road, Kaohsiung 80708, Taiwan. email: yjjong@kmu.edu.tw

Learning Point for Clinicians

Childhood-onset mitochondrial encephalomyopathies usually present with a progressive course with a fatal outcome. These assumed irreversible conditions prompt clinicians and parents to face end-of-life decisions for a young child. However, this unfortunate situation can be overcome via a molecular diagnosis that can grant a favorable prognosis with continuing intensive supportive care.

lactate was 9.6 mmol/l (normal reference: 0.5–2.2) and the creatine kinase (CK) 700 U/l (normal reference: 200). Muscle biopsy from the biceps brachii suggested a mitochondrial myopathy with cytochrome c oxidase (COX) deficiency (Figure 1). Full mitochondrial DNA (mtDNA) sequencing isolated from blood leukocytes was performed and a m.14674T>C mt-tRNA^{Glu} mutation was identified. This mutation was further confirmed by polymerase chain reaction (PCR)/restriction fragment length polymorphism (RFLP) analysis. Similarly, this mutation was also identified in the mother; however, the whole maternal families were asymptomatic. Subsequently, despite repeated PICU admissions for respiratory support over a 12-month period, his condition gradually improved. Head control was achieved at 5 months. At 8 months of age, nasogastric tube feeding and the ventilator were discontinued. He could sit independently at 10 months and could walk at 16 months. By 1 year of age, his serum lactate returned to normal. Currently, at 4.5 years of age, he has no prominent myopathic features and can run steadily without fatigue.

Case report

Patient 1

A 6-week-old boy was admitted to the pediatric intensive care unit (PICU) for frequent choking and apnea, requiring gavage feeding and assisted ventilation. He developed generalized weakness and sucking difficulties soon after birth. He exhibited profound hypotonia and hyporeflexia. The serum

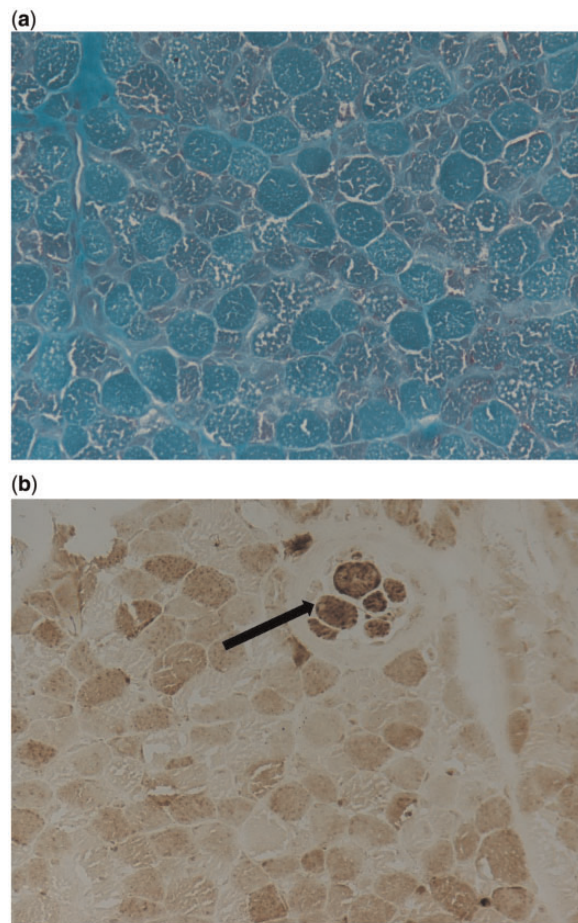


Figure 1. Muscle biopsy from biceps brachii of Patient 1 obtained at 2 months (both magnification $\times 400$): (a) The modified Gomori trichrome stain showing marked fiber-size variation and numerous ragged-red fibers. (b) Histochemical staining of COX showing virtually absence in all muscle fibers except for the intrafusal spindle (arrow).

Patient 2

A 14-day-old girl was admitted for respiratory distress together with high serum lactate (12.0 mmol/l) but normal CK. Subsequently, poor bulbar function and respiratory distress required frequent PICU admissions over an 8-month period. A muscle biopsy from the biceps brachii indicated COX-deficiency mitochondrial myopathy. The genetic analysis also confirmed a m.14674T>C mt-tRNA^{Glu} mutation by PCR/RFLP method. Her mother and maternal families were asymptomatic. Accordingly, the parents were reassured with the favorable prognosis and intensive supportive care was continued. She was weaned from artificial ventilation and gavage feeding at 10 months of age. Currently, at 3 years of age, she can run slowly.

Discussion

The early infantile onset of mitochondrial diseases is often associated with lethal encephalomyopathy and multi-organ involvement, leading to death in early childhood.¹ Deficiency of mitochondrial COX, a multisubunit assembly present in the inner membrane, usually causes progressive symptoms, called infantile fatal form. Interestingly, a distinct subtype, termed infantile reversible COX-deficiency myopathy, is characterized by spontaneous improvement both in clinical and pathological features. The floppy infant syndrome invariably manifests, requiring vigorous intensive care in infancy; however, spontaneous improvement ensues and the children are usually normal by 2 or 3 years of age.^{2,3} The causative gene has been recently identified as homoplasmic m.14674T>C or m.14674T>G mt-tRNA^{Glu} mutation.^{4,5} This simple genetic test is crucial for prognosis and management, because both clinical and histopathological features between fatal and benign reversible COX-deficiency myopathies are indistinguishable in infancy.

In conclusion, we suggest that screening for this mutation is imperative for floppy infants with suspected mitochondrial myopathy. Diagnosis of reversible COX-deficiency myopathy at the molecular level warrants pediatric neurologists and intensivists to efficiently identify children with a favorable outcome for continuing respiratory support from those with fatal mitochondrial presentation in infancy.

Conflict of interest: None declared.

References

1. Tulinius M, Oldfors A. Neonatal muscular manifestations in mitochondrial disorders. *Semin Fetal Neonatal Med* 2011; **16**:229–35.
2. DiMauro S, Nicholson JF, Hays AP, Eastwood AB, Koenigsberger R, DeVivo DC. Benign infantile mitochondrial myopathy due to reversible cytochrome c oxidase deficiency. *Trans Am Neurol Assoc* 1981; **106**:205–7.
3. Zeviani M, Peterson P, Servidei S, Bonilla E, DiMauro S. Benign reversible muscle cytochrome c oxidase deficiency: a second case. *Neurology* 1987; **37**:64–7.
4. Horvath R, Kemp JP, Tuppen HA, Hudson G, Oldfors A, Marie SK, et al. Molecular basis of infantile reversible cytochrome c oxidase deficiency myopathy. *Brain* 2009; **132**:3165–74.
5. Mimaki M, Hatakeyama H, Komaki H, Yokoyama M, Arai H, Kirino Y, et al. Reversible infantile respiratory chain deficiency: A clinical and molecular study. *Ann Neurol* 2010; **68**:845–54.