

Case Report

New vascular ring connectors in surgery for intramural haematoma of the abdominal aorta progressing to rupture

CHIH-HSIEN LEE, LI-WEI KO, YI-CHANG LIN, CHIH-CHIEN YEN, HSIANG-YU YANG, CHIH-HONG KAO, CHIEN-SUNG TSAI, YI-TING TSAI

Abstract

Aortic intramural haematoma is similar to classic aortic dissection, which causes a life-threatening medical condition, and immediate diagnosis and treatment are crucial. The optimal therapy for intramural haematoma of the abdominal aorta remains controversial. Conservative medical management is usually the first choice of treatment for uncomplicated cases. Surgical intervention is usually required for complicated intramural haematomas of the abdominal aorta, including conventional open repair and endovascular treatment with stent-grafts. A new vascular ring connector that achieves a quick, blood-sealed and sutureless anastomosis has been designed for aortic dissection. We herein report a case of intramural haematoma of the abdominal aorta, progressing to rupture on day 14 after onset, which had successful aortic repair with the new vascular ring connector. The new vascular ring connector could be an alternative method for the treatment of complicated intramural haematomas of the abdominal aorta.

Keywords: aortic dissection, intramural haematoma, vascular ring connector

Submitted 3/4/12, accepted 19/6/13

Cardiovasc J Afr 2013; 24: e1–e3

www.cvja.co.za

DOI: 10.5830/CVJA-2013-049

Department of Cardiac Surgery, Tungs' Taichung Metro-Harbor Hospital, Taipei, Taiwan

CHIH-HSIEN LEE, MD

Department of Biological Science and Technology, National ChiaoTung University, Taipei, Taiwan

CHIH-HSIEN LEE, MD

LI-WEI KO, PhD

Division of Cardiovascular Surgery, Department of Surgery, Tri-Service General Hospital, National Defense Medical Centre, Taipei, Taiwan

CHIH-HSIEN LEE, MD

YI-CHANG LIN, MD

CHIH-CHIEN YEN, MD

HSIANG-YU YANG, MD

CHIH-HONG KAO, MD

CHIEN-SUNG TSAI, MD

YI-TING TSAI, MD, cvsallen@mail.ndmctsg.edu.tw

Aortic intramural haematoma (IMH) develops as a result of spontaneous rupture of the vasa vasorum of the aorta or rupture of an atherosclerotic plaque.¹ Conservative medical management is usually the first choice of treatment for Stanford type B acute aortic dissection without complications.

IMH has been recommended to be managed according to the same guidelines as classic dissection.² However, IMH evolves very dynamically in the short term to regression, classic dissection, or aortic rupture.¹ Surgical intervention is usually required for complicated intramural haematomas of the abdominal aorta, including conventional open repair and endovascular treatment with stent-grafts.

A new vascular ring connector (Vasoring, Sunwei Technology Co, Taipei, Taiwan) has been designed for aortic dissection.³ It is a titanium ring that is used as a stent in the vascular graft to achieve a quick, blood-sealed and sutureless anastomosis. We herein report a case of intramural haematoma of the abdominal aorta, progressing to rupture on day 14 after onset, which was successfully surgically repaired with the new vascular ring connector.

Case report

A 49-year-old man with a past history of hypertension without regular medical control presented to our hospital with acute, intense epigastric and back pain for six hours. On admission, his blood pressure was 180/110 mmHg and pulse rate was 78 beats per minute. Physical examination of the chest and abdomen showed no signs of visceral ischaemia. Peripheral arterial pulses were easily palpable in the upper and lower extremities.

Laboratory data were unremarkable. Initial contrast-enhanced computed tomography (CT) showed a focal wall thickening from the descending aorta to the left common iliac artery without a demonstrable intimal flap or false lumen. On suspicion of an intramural haematoma of the abdominal aorta, the patient was admitted to the medical intensive care unit for blood pressure control and further evaluation.

On day 14 after onset, the patient complained of recurrent refractory abdominal pain. Physical examination of the abdomen revealed intractable tenderness and normal bowel sounds. Arterial pulsations in both lower limbs were palpable. A follow-up contrast-enhanced CT (Fig. 1) showed aortic dissection with a large primary entry tear in the infra-renal section of the abdominal aorta, extending to the bifurcation of the distal abdominal aorta.

The patient received emergency open surgery with the traditional open procedure before anastomosis. We used a

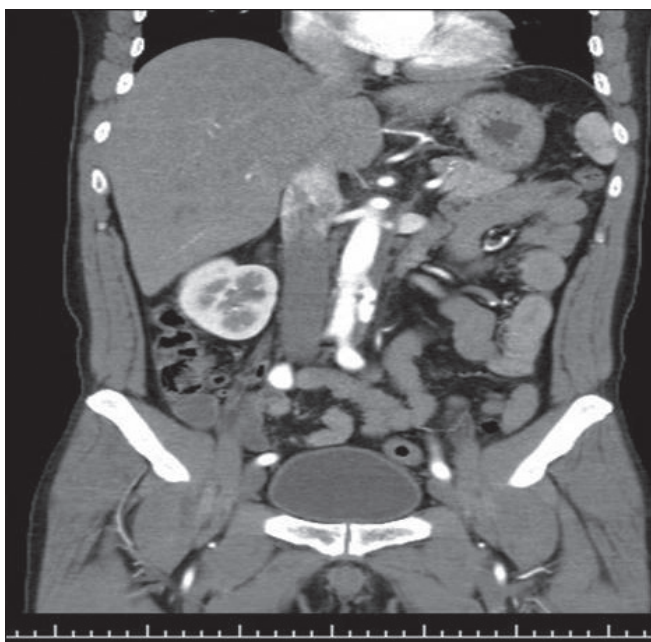


Fig. 1. A follow-up contrast-enhanced CT showing aortic dissection with a large primary entry tear in the infrarenal site of the abdominal aorta, extending to the bifurcation of the distal abdominal aorta on day 14 after onset.

vascular graft (Hemashield, Boston Scientific, Boston, MA, USA) with new vascular ring connectors (VRC). The VRC was attached to the vascular prosthesis by securing the edge of the graft against the narrow groove of the VRC with non-absorbable sutures. The ringed prosthesis was then inserted into the abdominal aorta, positioned at the planned proximal anastomotic site, and fixed to the abdominal aorta by tying the tapes against the wider groove. A similar manoeuvre was used for the distal anastomosis. The patient was well without deficit at the one-year follow up (Fig. 2).

Discussion

IMH results either from spontaneous rupture of the vasa vasorum of the aorta, causing haemorrhage within the aortic wall in the absence of initial intimal disruption, or from a penetrating atherosclerotic ulcer that penetrates into the internal elastic lamina and allows haematoma formation within the media of the aortic wall.^{4,7} IMH is a variant form of aortic dissection, and although less common, accounts for 10–30% of cases. It has been accepted as an increasingly recognised and potentially fatal entity of all acute aortic syndromes.^{4,7} Penetrating atherosclerotic ulcer of the IMH was reported to have a significantly progressive course.^{5,6} In our experience, IMH due to a penetrating atherosclerotic ulcer commonly had a progressively downhill clinical course.

IMH has a variable clinical course. It commonly affects elderly patients (mean age 66 years) with a history of hypertension.^{5,6,8} The most common presenting symptom is sudden onset of abdominal pain radiating to the back or the buttock.⁵ In our experience, onset of recurrent/refractory pain may be a sign of impending rupture and should therefore be considered for more aggressive intervention.

With recent advances in imaging techniques, IMH is now increasingly recognised. CT scans diagnose aortic dissection

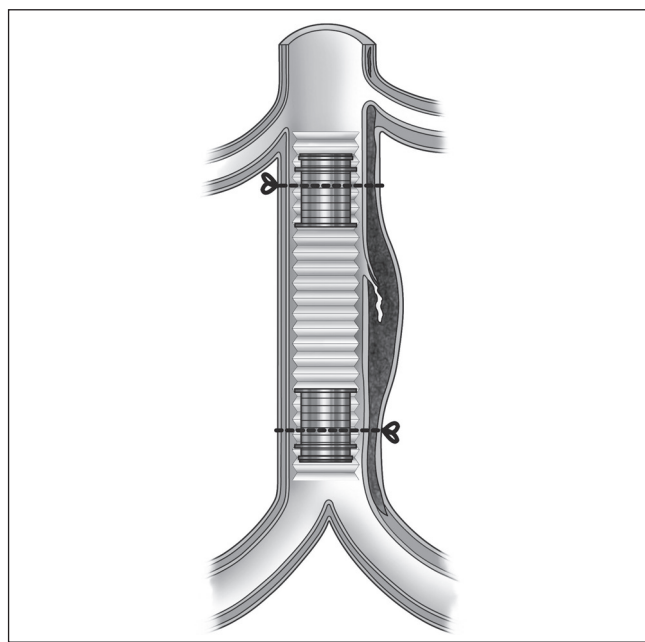


Fig. 2. The ringed graft is inserted into the aorta and the braided nylon tapes are tied against the wider groove of the vascular ring connectors to achieve a sutureless anastomosis.

reasonably well but may not be completely reliable in distinguishing IMH from classic aortic dissection.⁸ Aortography was performed, which showed no evidence of dissection but did reveal an ectatic descending aorta. With MRI, IMH is characteristically seen as a focal thickening of the aortic wall in the absence of dissection.⁸ It should be considered in the differential diagnosis of any patient with an acute onset of abdominal pain, radiation to the back or buttocks, with the presence or absence of a pulsatile abdominal mass or signs of limb ischaemia.

Most authorities currently recommend treatment of IMH similar to that of classic aortic dissection, with early surgery for patients with proximal IMH and medical management for patients with distal IMH.⁸ Initially stable patients with IMH of the abdominal aorta can be treated medically with frequent clinical and radiological re-assessment and they may have complete resolution.

A certain volume of haematoma in the aortic wall may cause the intima of the penetrating atherosclerotic ulcer to become fragile and lead to intimal disruption.¹ Consequently IMH weakens the aorta and may progress to aortic dissection. This may explain why wall thickness is related to progression to overt dissection or aortic rupture. IMH may progress to classic dissection (i.e. with intimal disruption) in up to 33% of cases.^{5,8} In our case, intramural haematoma of the abdominal aorta progressed to rupture with medical failure.

Conservative medical management is usually the first choice of treatment for Stanford type B acute aortic dissection without complications, but surgical intervention is required in patients with complications, such as leakage or threatened rupture, malperfusion, persistent pain or intractable and progressive enlargement of the ulcer-like projection to more than 20 mm in diameter or depth during the follow-up period.^{1,2,8}

Operative intervention includes open or endovascular repair of the abdominal aorta. The open technique usually involves

placement of a Dacron graft, although resection of the affected aorta with end-to-end anastomosis without graft insertion has been described.⁹ This decision is greatly influenced by anatomical conditions together with the surgeon's experience. It is unclear what benefit endovascular stenting would have in the treatment of IMH.⁸ The fragile tissue makes suturing of the vascular prosthesis to the vascular wall difficult. Bleeding from the aortic anastomosis may lead to uncontrollable bleeding and even death.

A new vascular ring connector (Vasoring, Sunwei Technology Co, Taipei, Taiwan) has been designed for aortic dissections.³ In the series of Wei and co-workers,¹⁰ the VRC may improve mid-term results of aortic dissection by reducing both the anastomosis time and the risk of bleeding.

The VRC is composed of a biocompatible titanium alloy that has two grooves on the outside of the VRC.³ The device is inserted into a vascular prosthesis to form an intraluminal graft and is fixed against the narrow groove with a non-absorbable suture. The narrow groove is designed for better external fixation. Then braided tape, tied around the overlapping region of the abdominal aorta and the VRC at the wider groove, provides a sutureless anastomosis and homogenous contact surface. The time of anastomosis is shorter than with conventional surgery.

We used the VRC for the first time in this case of the IMH that progressed to dissected abdominal aorta. The results provide evidence that the VRC is a promising method of treatment for IMH of the abdominal aorta progressing to rupture.

Conclusion

Aortic IMH is a difficult diagnosis that requires a high index of suspicion. The vascular ring connector may improve the results of aortic dissection by reducing both the anastomosis time and

the risk of bleeding. It is an alternative method for the treatment of dissected abdominal aorta.

References

1. Moizumi Y, Komatsu T, Motoyoshi N, Tabayashi K. Clinical features and long-term outcome of type A and type B intramural hematoma of the aorta. *J Thorac Cardiovasc Surg* 2004; **127**: 421–427.
2. O'Gara PT, DeSanctis RW. Acute aortic dissection and its variants. Toward a common diagnostic and therapeutic approach. *Circulation* 1995; **92**: 1376–1378.
3. Wei J, Chang CY, Chuang YC, Sue SH, Lee KC, Tung D. A new vascular ring connector in surgery for aortic dissection. *J Thorac Cardiovasc Surg* 2009; **138**: 674–677.
4. Evangelista A, Dominguez R, Sebastia C, Salas A, Permanyer-Miralda G, Avegliano G, *et al.* Long-term follow-up of aortic intramural hematoma: predictors of outcome. *Circulation* 2003; **108**: 583–589.
5. Baikoussis NG, Apostolakis EE, Siminelakis SN, Papadopoulos GS, Goudevenos J. Intramural haematoma of the thoracic aorta: who's to be alerted the cardiologist or the cardiac surgeon? *J Cardiothorac Surg* 2009; **4**: 54–61.
6. Ganaha F, Miller DC, Sugimoto K, Do YS, Minamiguchi H, Saito H, *et al.* Prognosis of aortic intramural hematoma with and without penetrating atherosclerotic ulcer: a clinical and radiological analysis. *Circulation* 2002; **106**: 342–348.
7. Song JK. Diagnosis of aortic intramural haematoma. *Heart* 2004; **90**: 368–371.
8. Sawhney NS, DeMaria AN, Blanchard DG. Aortic intramural hematoma: an increasingly recognized and potentially fatal entity. *Chest* 2001; **120**: 1340–1346.
9. Trimarchi S, Eagle KA, Nienaber CA, Pyeritz RE, Jonker FH, Suzuki T, *et al.* Importance of refractory pain and hypertension in acute type B aortic dissection: insights from the International Registry of Acute Aortic Dissection (IRAD). *Circulation* 2010; **122**: 1283–1289.
10. Wei J, Chang CY, Chuang YC, Sue SH, Lee KC, Wu CW, *et al.* Midterm results of vascular ring connector in open surgery for aortic dissection. *J Thorac Cardiovasc Surg* 2012; **143**: 72–77.